

# Cataract & Refractive Surgery

**EUROPE**

**TODAY**

## Challenges in IOL Surgery

**A worldwide panel of surgeons deliberates on treatment options to accommodate patients' personalities and expectations.**

With contributions from Jorge L. Alió, MD, PhD; Roberto Bellucci, MD; Francesco Carones, MD; Charles Claoué, MA(Cantab), MD, DO, FRCS, FRCOphth, FEBO, MAE; Jose L. Güell, MD; Oliver K. Klaproth, Dipl Ing(FH); Thomas Kohnen, MD; Frederico F. Marques, MD, PhD; Daniela M.V. Marques, MD, PhD; Erik L. Mertens, MD, FEBOphth; Tobias H. Neuhann, MD; Mark Packer, MD, FACS; Magda Rau, MD; Marie-José Tassignon, MD, PhD, FEBO; William B. Trattler, MD; Abhay R. Vasavada, MS, FRCS; and Robert J. Weinstock, MD

Presort Standard  
U.S. Postage  
Paid  
Harrisburg, PA  
Permit 1113

INTRAOCULAR FEMTOSECOND LASER APPLICATIONS IN CATARACT SURGERY



# Challenges in IOL Surgery

A panel of surgeons presents rationales for treatment choices in thought-provoking cases.

BY JORGE L. ALIÓ, MD, PhD; ROBERTO BELLUCCI, MD; FRANCESCO CARONES, MD; CHARLES CLAOUÉ, MA(CANTAB), MD, DO, FRCS, FRCOPHTH, FEBO, MAE; JOSE L. GÜELL, MD; OLIVER K. KLAPROTH, DIPL ING(FH); THOMAS KOHNEN, MD; FREDERICO F. MARQUES, MD, PhD; DANIELA M.V. MARQUES, MD, PhD; ERIK L. MERTENS, MD, FEBOPHTH; TOBIAS H. NEUHANN, MD; MARK PACKER, MD, FACS; MAGDA RAU, MD; MARIE-JOSÉ TASSIGNON, MD, PhD, FEBO; WILLIAM B. TRATTLER, MD; ABHAY R. VASAVADA, MS, FRCS; AND ROBERT J. WEINSTOCK, MD

*As IOL choices proliferate, modern surgeons are challenged to stay abreast of the latest developments in lens surgery. Aspheric, multifocal, accommodating, toric, and supplementary (ie, piggy-back) IOL designs—as well as combinations of those features—are now available from multiple manufacturers. With patients becoming increasingly knowledgeable about the options available to them, surgeons must know what their best choices are when faced with challenging cases. CRST Europe convened a panel of experts to discuss their preferences and the options they would present to patients with a variety of challenging refractive demands. The cases were suggested by William B. Trattler, MD, Editorial Board of CRST Europe's sister publication in the United States. Our panel of experts, including lens surgeons from around the world, presents a diverse range of opinions in this lively virtual roundtable format.*

**Case Study No. 1: A 68-year-old hyperope with visually significant cataract visits your clinic. He uses a computer at work most of the day. How would you treat him?**

**JORGE L. ALIÓ, MD, PhD**

Hyperopes are excellent candidates for the Crystalens HD (Bausch & Lomb, Rochester, New York). This patient has a need for excellent intermediate distance vision, which is best provided by this lens compared with other

accommodating or multifocal IOL designs. We have previously reported the reasons why improved outcomes should be obtained with the Crystalens in hyperopes.<sup>1</sup>

1. Alió JL, Patel S. Some factors governing the efficacy of positional pseudoaccommodative intraocular lenses. *Ophthalmology*. 2005;112(11):2009-2014.

**ROBERTO BELLUCCI, MD**

My preferred choice for this patient would be the AcrySof IQ Restor +3.0 D IOL (Alcon Laboratories, Inc., Fort Worth, Texas). This lens is aspheric, meaning a sharper image at the distance focus and better separation between the distance and near foci (which made it possible to reduce the near add). This is the best multifocal IOL for computer reading, although patients may require a 1.00 D add for near vision. There is a short learning curve with this lens, which may limit patient satisfaction before second eye surgery. Multifocal or accommodating lenses work well after bilateral implantation, and I always tell the patient that, with this surgery, "One plus one is three."

**FRANCESCO CARONES, MD**

In this case, if the patient does not aim at full spectacle independence, I would consider implanting a monofocal aspheric IOL, such as the AcrySof IQ. I would probably target the final refraction at -1.50 to -2.00 D in both eyes if he desires to work at the computer without wearing glasses or at emmetropia if working-distance spectacle independence is not crucial.



**CHARLES CLAOUÉ, MA(CANTAB), MD, DO, FRCS, FRCOPHTH, FEBO, MAE**

Note that this patient is working beyond retirement age. As a hyperope, he would be good candidate for a multifocal IOL if he wishes to be spectacle independent. Depending on his other daily activities, I would suggest either blended vision using the M-Flex +3 (Rayner Intraocular Lenses, Ltd., East Sussex, United Kingdom) in the dominant eye and the M-Flex +4 in the nondominant eye. However, if he does not do a lot of reading or other near vision tasks, I would implant the M-Flex +3 in both eyes.

If the patient is a large individual, his working distance is likely to be greater than the average patient's. Therefore, I would be swayed toward bilateral implantation of the aspheric M-Flex +3. Conversely, a small individual with short arms would probably be happier with the +4 add. Both IOLs have a low incidence of unwanted visual effects such as halos, probably because of the material's refractive index. The lens' 360° square-edge design reduces the rate of posterior capsular opacification (PCO).

**JOSE L. GÜELL, MD**

In this case, I would opt for blended monovision, aiming for plano in the dominant eye and -0.75 D in the nondominant. To achieve this, I prefer using aspheric monofocal IOLs; however, I might also consider using standard IOLs or the Light Adjustable Lens (LAL; Calhoun Vision, Inc., Pasadena, California). Corneal refractive surgery may be necessary after IOL implantation to achieve this refractive state.

**OLIVER K. KLAPROTH, DIPL ING(FH); AND THOMAS KOHNEN, MD**

Quality of vision has become a major issue in both cataract and refractive surgery. We no longer aim simply for the removal of cataracts or correction of ametropia. Ophthalmologists try to provide their patients superior functional vision based on the patient's expectations and environment in daily life. This is why individual patient education and responsible patient selection has become a major issue in cataract and refractive surgery.

In this case, three types of treatment should be taken into consideration. Because the patient is hyperopic and intermediate visual acuity is of special interest for him, he seems to be a perfect candidate for the Crystalens HD. This lens provides both excellent near and intermediate visual acuity. However, another option would be the AcrySof IQ Restor +3.0 D multifocal IOL. With its modified addition of 2.50 D in the spectacle plane, it provides excellent intermediate visual acuity. We have successfully used the +3.0 D IOL in similar cases. Although this IOL may cause more optical side effects compared with the Crystalens HD, in our clinical

experience, the AcrySof IQ Restor +3.0 D provides much better near visual acuity and, thus, a larger range of application. Furthermore, we have not seen any major complaints about photic phenomena (eg, halos, glare) with the lens when patient selection has been performed with care.

The last option would be implantation of two standard IOLs using the principle of monovision. In this case, a contact lens trial should be performed prior to surgery.

**FREDERICO F. MARQUES, MD, PHD; AND DANIELA M.V. MARQUES, MD, PHD**

In this case, there are two appropriate options that would correct presbyopia as well as the cataract. The first one is use of pseudophakic monovision, where the dominant eye is planned for distance with emmetropia (spherical equivalent [SE],  $\pm 0.50$  D) and the second eye is planned for near (SE, -2.00 D). We have been using pseudophakic monovision with the aspheric monofocal Tecnis ZA 9003 (Abbott Medical Optics Inc., Santa Ana, California) since 2005, with great patient acceptance and satisfaction. Patients achieve better contrast sensitivity under mesopic conditions. Recently, we published a paper demonstrating overall satisfaction in 97.4% of patients, with 92.1% reaching spectacle independence at a UCVA of 20/30 or better and near UCVA of J2 or better. Moreover, 90% of patients could not read at J3 (0.67 m) with unremarkable stereo acuity reduction.<sup>1</sup>

The second option is to implant bifocal IOLs bilaterally to reduce the spectacle dependence. We use either the aspheric Restor or the aspheric Tecnis ZMA00 or combine both IOLs. The Restor has a diffractive/refractive optical zone providing optimal distance vision; however, reading speed is limited under mesopic conditions. By contrast, the Tecnis ZMA has a full diffractive optical zone that provides better vision under mesopic conditions, especially for reading. In our experience, bilateral Tecnis ZMA00 has been used successfully in most cases. In some cases, we decided to mix and match IOLs, depending on the patient's expectations and comprehension.

1. Marques FF, Marques DMV, et al. Evaluation and performance of pseudophakic monovision technique in patients submitted to cataract surgery. *Arq Bras Ophthalmol*. 2009;72(2):164-168.

**ERIK L. MERTENS, MD, FEBOPHTH**

This is an ideal case to treat with the Crystalens HD accommodating IOL. I would aim for plano in the dominant eye and -0.25 to -0.50 D in the nondominant. Any corneal cylinder must be treated properly by placing the incision at the steepest axis and performing a counterincision if the cylinder is more than 1.00 D.

**TOBIAS H. NEUHANN, MD**

Before I discuss the different options of visual rehabilitation with the patient, I try to get more detailed infor-



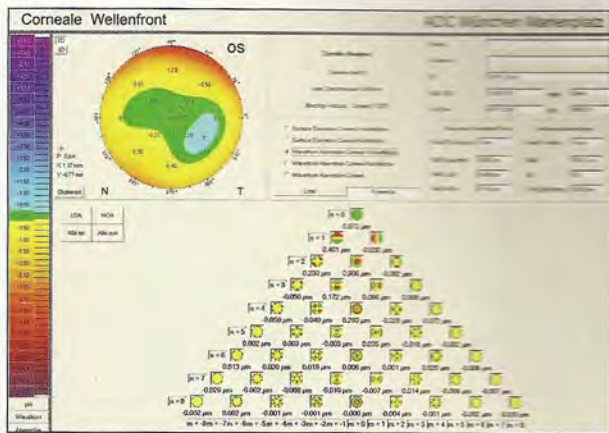


Figure 1. Zernike tree of the higher- and lower-order aberrations of the cornea. Spherical aberration of the anterior, posterior, or the complete cornea can be separately displayed.



Figure 2. Preoperative existing corneal guttata can limit the postoperative result.

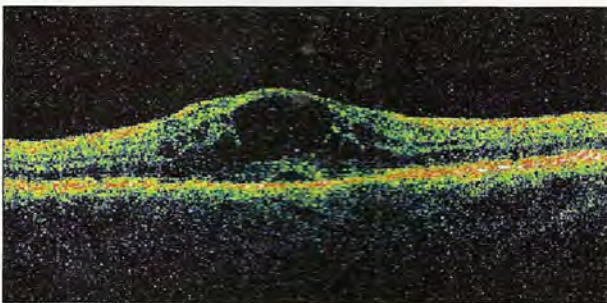


Figure 3. Preoperative existing macula disease can limit the postoperative result.

mation about the anatomy and optics of his eyes.

**First step.** Noncontact biometry (IOLMaster; Carl Zeiss Meditec, Jena, Germany), endothelial cell count, and retinal optical coherence tomography (OCT; Figure 1) should be performed, together with a pure corneal wavefront measurement (which is available as a new update on the Pentacam HR [Oculus Optikgeräte GmbH,

Wetzlar, Germany]). The endothelial cell count is performed to decipher if the cornea will survive the surgery in good condition (Figure 2); the retinal OCT is done to be sure that the macula is healthy (Figure 3).

**Second step.** If OCT and endothelial cell count are good, I look for the spherical corneal aberration (Zernike 4). For example, an aberration of  $0.27 \mu\text{m}$  tells me what aspheric monofocal IOL I will choose.

**Third step.** After having discussed with the patient his postoperative expectations, I propose—on the basis of the results—a new-technology IOL. The aim is to find a customized aspheric IOL design, which may be a monofocal, toric, or multifocal IOL.

To answer to the question: For emmetropia with the use of reading glasses or monovision in this case, I would choose the Tecnis 1-Piece because of its asphericity ( $-0.27 \mu\text{m}$ ).

#### MARK PACKER, MD, FACS

The options I would present to this patient include (1) bilateral distance-focused aspheric monofocal IOLs with spectacles for intermediate and near vision or (2) bilateral aspheric multifocal IOLs. I do not recommend monovision to someone who has no experience with it, and I do not like the concept of bilateral intermediate-focus IOLs with the need for both near and distance glasses.

I have found less predictability and a greater need for reading glasses with the Crystalens in hyperopes.<sup>1</sup> With the Tecnis Multifocal (Tecnis MF) IOL in both eyes, there is an 88% chance of complete freedom from glasses at 4 to 6 months.<sup>2</sup> With the AcrySof IQ Restor +3.0 D IOL in both eyes, there is a 76% chance of complete freedom from glasses, and defocus studies show that the intermediate range acuity is higher than with the Tecnis MF.<sup>3</sup> If the patient prefers spectacle-free computer distance with the understanding that a pair of glasses may still be needed for fine print, then the AcrySof IQ Restor +3.0 D would be a good choice; otherwise, Tecnis MF offers the best option.

1. Packer M. Frequency and risk factor analysis of piggyback IOL enhancement following refractive lens exchange with an accommodative IOL. *Refractive Surgery 2006: The Times They Are A-Changin'*. Paper presented at: International Society of Refractive Surgery of the American Academy of Ophthalmology (ISRS/AAO); Las Vegas; November 10-11, 2006.

2. Tecnis Multifocal Intraocular Lens. US FDA Web site. Summary of Safety and Effectiveness. Data Available at: <http://www.fda.gov/cdrh/pdf8/P080010b.pdf>. Accessed July 17, 2009.

3. Package insert. AcrySof IQ ReSTOR Multifocal IOL. Fort Worth, Texas; Alcon Laboratories, Inc.

#### MAGDA RAU, MD

For this patient, I would choose the ReZoom Multifocal IOL (Abbott Medical Optics Inc.). This refractive, distance-dominant IOL provides the most chance for spectacle independence during computer work and the best intermediate vision (Figures 4 and 5). I would first implant the refractive ReZoom Multifocal IOL into the dominant eye, with follow-up 4 to 6 weeks later. If



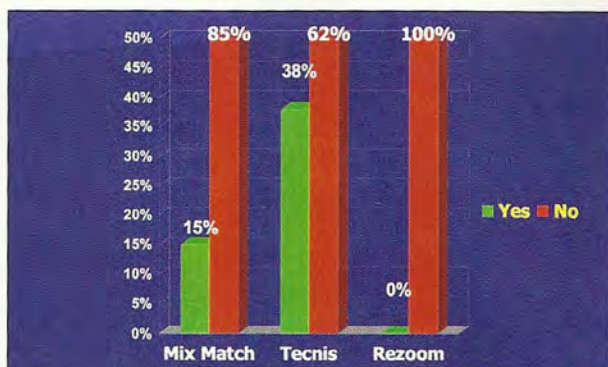


Figure 4. In Dr. Rau's study, 85% of patients in the mix-and-match group, 62% of patients in the Tecnis group, and 100% of patients in the ReZoom group did not need glasses for computer use.

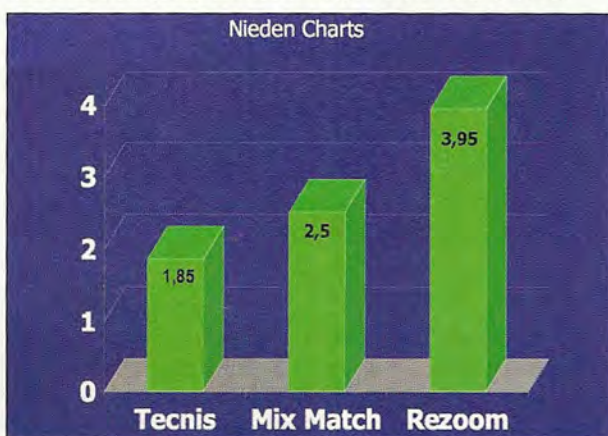


Figure 6. Mean UCVA for near (3 months postop).

the patient is satisfied with his results with the multifocal IOL, then I would implant the same IOL in the nondominant eye. The IOL power calculation is optimized based on already available data. If a slight improvement in near vision is desired, I calculate the refractive multifocal IOL slightly in the minus range (-0.50 D). If the patient wants much better near vision, I would combine the ReZoom multifocal with the Tecnis IOL (Figures 6 and 7).

**MARIE-JOSÉ TASSIGNON, MD, PHD, FEBO**

This patient can choose among three options: (1) monofocal IOLs aiming at emmetropia, (2) monofocal IOLs calculated for monovision, or (3) pseudoaccommodating IOL. My first choice for monofocal IOLs is the bag-in-the-lens (BIL; Morcher GmbH, Stuttgart, Germany). This lens provides excellent far and intermediate vision and relatively good intermediate vision for desktop computer reading, especially in hyperopic eyes. In addition, this lens guarantees no PCO and allows active IOL alignment. Monovision in hyperopes is less well accepted than in myopes.

My first choice for pseudoaccommodating IOLs is combined implantation of the BIL and a multizonal sul-

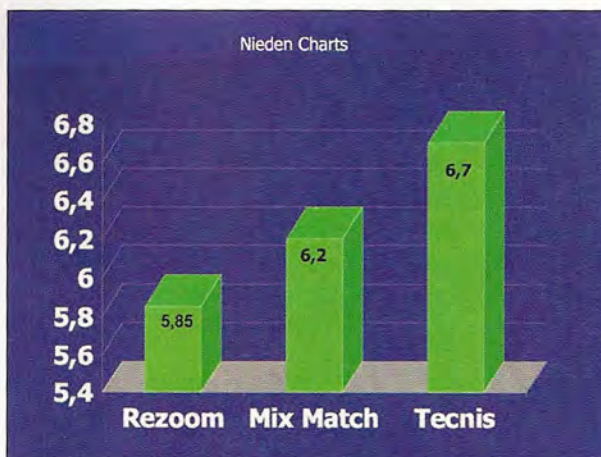


Figure 5. Mean UCVA for intermediate (3 months postop).

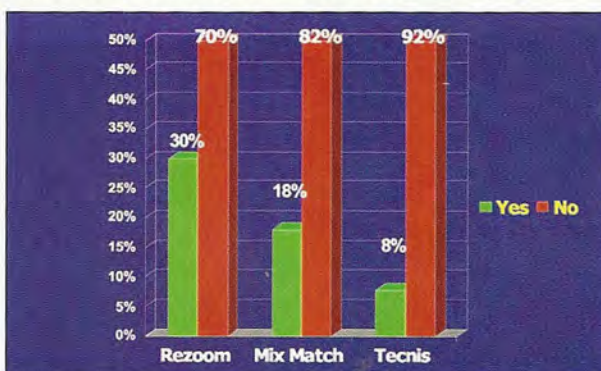


Figure 7. In Dr. Rau's study, 70%, 82%, and 92% of patients in the ReZoom, mix-and-match, and Tecnis groups, respectively, did not need reading glasses for small print.

cus-fixated supplementary lens, the Sulcoflex (Rayner Intraocular Lenses, Ltd.). This last solution is reversible; explantation is easy in case the patient cannot adapt to the multizonal lenses.

**WILLIAM B. TRATTLER, MD**

Assuming that the cornea and macula are healthy, I would recommend one of three IOL technologies. The AcrySof IQ Restor +3.0 D, recently approved in the United States, provides both distance and intermediate vision. I would target plano, which provides the best near vision at 40 to 50 cm (16-20 inches). An alternative option would be the Crystalens HD, which also provides good distance and intermediate vision and is available to my patients in the United States. Lastly, I was an investigator in the US Food and Drug Administration (FDA) study of the Tetraflex (Lenstec, Inc., St. Petersburg, Florida), and this technology provided good distance and intermediate vision, with some patients also obtaining good near vision. With these options, I would advise my patient that they may require glasses for reading small print.



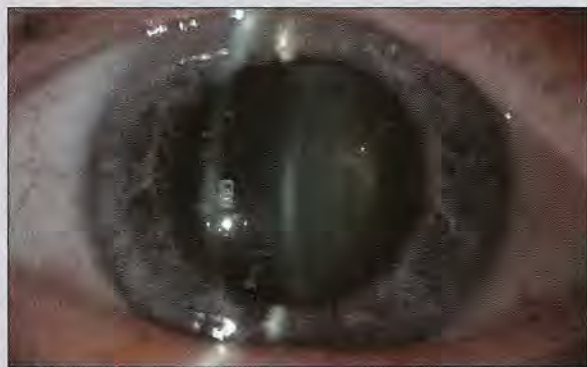## ABHAY R. VASAVADA, MS, FRCS

If the patient is motivated by spectacle independence, then I would implant the AcrySof IQ Restor +3.0 D multifocal IOL after discussing with him the potential benefits and problems of multifocal IOLs. Implanting this particular IOL will provide the patient with excellent distance and near visual acuity and good intermediate vision. Our experience with the AcrySof IQ Restor +3.0 D has been quite favorable, even in terms of intermediate vision.

## ROBERT J. WEINSTOCK, MD

This patient is an ideal candidate for bilateral Crystalens implantation. With his lifestyle of heavy computer use, he should enjoy spectacle independence at work. With bilateral emmetropia, targeting his driving and distance vision should be excellent as well. The only caveat is that he will likely require light reading glasses for small print. If a mild monovision of -0.50 D is targeted in the nondominant eye, he may enjoy even more range of vision for near applications while preserving excellent distance vision.

### Case Study No. 2: A 42-year-old emmetrope with monocular cataract is scheduled for surgery. How would you treat this patient?



(Courtesy of Erik L. Mertens, MD, FEBOphth)

## JORGE L. ALIÓ, MD, PHD

Emmetropes are never happy with the contrast sensitivity loss that unilateral implantation causes. The Crystalens HD will provide excellent power and intermediate vision. Instruct the patient that near vision for small reading characters will probably be accomplished with low-add spectacles (1.00 or 1.50 D).

## ROBERTO BELLUCCI, MD

Provided the contralateral eye has no cataract, I believe the best lens for this patient is the Crystalens HD. This lens offers perfect distance vision and allows up to 1.50 D of accommodation. Our young patient will appreciate the retained ability to see closer objects that would compare with that of the contralateral eye.

## FRANCESCO CARONES, MD

I would go for an aspheric multifocal IOL, such as the AcrySof IQ Restor +3.0 D IOL. I suggest the 3.00 D add because it does not compromise intermediate vision.

## CHARLES CLAOUÉ, MA(CANTAB), MD, DO, FRCS, FRCOPHTH, FEBO, MAE

Assuming that the patient is symptomatic from his cataract, then the crucial factor is that he is in the prepresbyopic age group. As such, he is unlikely to be satisfied with the absolute presbyopia of a monofocal IOL. The choice is between an accommodating IOL and a multifocal. My experience with accommodating IOLs has confirmed the lack of unwanted visual effects;<sup>1</sup> however, the accommodative effect is limited and unpredictable. If the patient is opposed to spectacle dependence, then I would probably implant a modern aspheric multifocal IOL. If he is not concerned with wearing glasses, then a monofocal IOL would be my choice.

1. Clauoué, CMP. A prospective comparative evaluation of functional vision after cataract removal and implantation of the Array multifocal IOL or the 1CU Accommodative IOL. *J Cataract Refract Surg*. 2004;30:2088-2091.

## JOSE L. GÜELL, MD

Here we need to know why the monocular cataract appeared. Assuming that potential visual acuity is 20/20, I would use a monofocal aspheric IOL with the same considerations as case study No. 1 regarding dominance.

## OLIVER K. KLAPROTH, DIPL ING(FH); AND THOMAS KOHNEN, MD

In this case, most of the information from case study No. 1 can be used as well. The first option is implantation of the AcrySof IQ Restor +3.0 D in the cataractous eye; however, the patient may experience optical phenomena in the operated eye. Refractive lens exchange in the contralateral eye may be a solution.

Implanting an accommodating IOL such as the Crystalens HD is another potential solution for the patient. This strategy may solve the problem of optical side effects caused by multifocal IOLs. Furthermore, the accommodative effect of the IOL may be more familiar for the patient. However, we have to take into account the amount of accommodation and the presbyopic correction in the second eye. For instance, cataract formation in the second eye may take another 20 to 30 years. In this case, unilateral implantation of a multifocal or accommodating IOL is the wrong option. Implantation of an aspheric IOL with prescription of intraindividual fitted reading or progressive spectacle lenses can be a sufficient and satisfying way to solve the patient's visual problems in this case.



**FREDERICO F. MARQUES, MD, PhD;  
AND DANIELA M.V. MARQUES, MD, PhD**

In our opinion, this is the ideal case for pseudophakic monovision because the fellow eye is emmetropic with UCVA close to 20/20. The patient is probably satisfied with his distance vision. Therefore, we would correct the monocular cataract with an aspheric monofocal IOL planned between -1.00 and -2.00 D. This value will depend on the patient's accommodation.

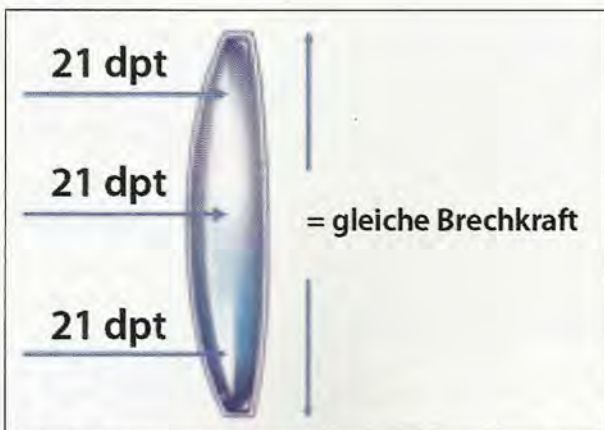
It is crucial to know how close the patient is to being able to read without correction in the good eye. If the patient has near UCVA of J1, it will be more difficult for him to understand the procedure and, in this particular situation, a bifocal IOL may be indicated. By contrast, if the patient's near UCVA is J3 or he is already dependent on reading glasses, we would recommend pseudophakic monovision.

**ERIK L. MERTENS, MD, FEBOPHTH**

This patient is rather young for developing a monocular cataract. Care should be taken to rule out trauma as the cause of the cataract because this could be associated with zonulolysis. If a significant zonulolysis is present, a premium IOL such as a multifocal or accommodating lens is not the first choice. I would use a capsular tension ring (CTR) to stabilize the bag and then implant a monofocal aspheric IOL. If the integrity of the bag is assured, my preference would be the Crystalens HD accommodating IOL, aiming for -0.25 to -0.50 D of ametropia. I will choose a multifocal IOL only if both eyes can be treated.

**TOBIAS H. NEUHANN, MD**

I would follow the same three steps I outlined in case study No. 1.



**Figure 8.** An aberration-neutral IOL keeps the individual asphericity of the patient's cornea without introducing the additive aberrations of the IOL.

After analyzing the measurements, the IOL design with the specifications closest to the results will be chosen. If it is a monofocal IOL, my first choice is an aspheric IOL design. If the spherical aberration is zero or close to zero, an aberration-free IOL would be ideal, such as the SofPort AO or the Akreos AO (both by Bausch & Lomb; Figure 8).

If the spherical aberration is positive (eg, 0.18  $\mu\text{m}$ ), an AcrySof IQ or AF1 Symm IOL (Hoya Surgical Optics, Frankfurt, Germany) IOL design would be the choice. Patients who previously underwent hyperopic LASIK should be corrected with a spherical IOL design.

**MARK PACKER, MD, FACS**

Younger patients do quite well with monocular multifocal IOL implantation. I have found this to be consistently true since I began using the multifocal Array (Abbott Medical Optics Inc.; no longer manufactured) in 1997. In this case, I would offer this patient either a monofocal aspheric distance-focused IOL or the Tecnis MF IOL. Because the patient may not yet have any experience with presbyopia, the need for a presbyopia-correcting IOL will require accurate counseling.

**MAGDA RAU, MD**

A significant problem for younger cataract patients who are still able to accommodate is the complete loss of accommodation after cataract surgery. The implantation of multifocal IOLs solves this problem. Therefore, this person is the ideal candidate for a multifocal IOL. Between 1999 and 2003, I implanted the multifocal Array in the eyes of young cataract patients with good long-term results. From this experience, I would now choose the second-generation ReZoom, which features five optical zones optimized to provide good vision across a range of distances. The lens allows more light to pass through for distance correction, which reduces nighttime halos and glare. The optimized aspheric transition between zones provides balanced intermediate vision. In my experience, patient satisfaction after implantation of this lens is higher than after implantation of the Array.

**MARIE-JOSÉ TASSIGNON, MD, PhD, FEBO**

Two solutions can be proposed. The first is a monofocal BIL, aiming for emmetropia if the eye is dominant or -0.50 or -0.75 D if the eye is nondominant. The second option is still a monofocal BIL; however, the eye is targeted for emmetropia with secondary implantation of the Sulcoflex. This combination yields the risk of poor acceptability by the patient, independent from whether the eye is dominant or nondominant.



### WILLIAM B. TRATTLER, MD

In my experience, it is often difficult for younger patients to appreciate a unilateral presbyopia-correcting IOL when the other eye is phakic and only mildly presbyopic. I would, therefore, discuss the option of a monofocal IOL with a target refraction of approximately -0.75 D. One interesting quandary is whether to use an aspheric or spherical monofocal. The aspheric will provide crisper vision; the monofocal without aspheric correction will provide slightly less crispness of vision yet slightly more depth of field.

### ABHAY R. VASAVADA, MS, FRCS

Because this emmetropic individual has a monocular cataract, he is a candidate for an aspheric monofocal IOL. This lens will provide excellent distance visual acuity and contrast sensitivity.

### ROBERT J. WEINSTOCK, MD

With a monocular cataract in an emmetrope, the obvious choice is a monofocal aspheric implant, such as the Akreos or the Tecnis. Target should be near emmetropia; monovision could be considered if the patient has used it in the past or a contact lens trial can be performed. I would avoid multifocal IOLs in a unilateral case. If the patient is willing to sacrifice some quality of distance vision, you could also consider the Crystalens with mild monovision targeting -1.00 D. This would likely eliminate the need for glasses, except for the smallest of print.

**Case Study No. 3: An emmetropic engineer with bilateral cataracts comes in for a consultation. He tells you that he drives a lot at night and he hates wearing glasses. How would you treat this patient?**

### JORGE L. ALIÓ, MD, PHD

This patient will be happy with good quality spectacle independence for far and intermediate vision, as computer vision is the range of vision most used by this patient. Even though he hates wearing glasses for near vision, a near vision add of approximately 1.00 to 1.50 D may be necessary for small characters. I would not recommend multifocal lenses for this patient.

### ROBERTO BELLUCCI, MD

Engineers, opticians, and photographers are among the most demanding patients. Therefore, I would prefer the Crystalens HD for this patient, avoiding both

refractive and diffractive bifocal optics. This is currently the best lens, providing near vision without impairing distance vision. For power calculation, I would recommend the Holladay 2 formula, which has provided the best results in my experience.

### FRANCESCO CARONES, MD

Detail-oriented patients, such as most engineers, do not represent good candidates for multifocal IOLs. These patients typically do not accept the slight compromises regarding quality of vision that multifocality implies. In this case, the engineer is also a hard driver; thus, I would choose an aspheric monofocal IOL for both eyes.

### CHARLES CLAOUÉ, MA(CANTAB), MD, DO, FRCS, FRCOPHTH, FEBO, MAE

We are not told what sort of engineer the patient is; the visual requirements of an electrical engineer and a construction engineer are dissimilar. However, this patient is motivated to find a solution to his cataracts that leaves him spectacle independent. Because the patient drives a lot at night, it raises a serious concern about implanting a multifocal IOL. As stated in case study No. 2, I do not believe current accommodating IOLs give adequately predictable results. Although I would present the option of multifocal IOLs to the patient, he would probably best be served by monofocal IOLs with refractive settings for monovision. I would warn the patient that he might want to leave a pair of glasses in the car for night driving.

### JOSE L. GÜELL, MD

I would treat this patient with blended monovision, using monofocal aspheric IOLs. I would aim for plano in the dominant eye and -0.25 D in the nondominant.

### OLIVER K. KLAPROTH, DIPL ING(FH); AND THOMAS KOHNEN, MD

Aspheric IOLs have superior optical quality under mesopic conditions. Thus, implantation of an aspheric IOL would probably be the best solution to provide optimal night-driving visual performance. Implantation of an accommodating IOL, such as the Crystalens HD, should be performed only after careful patient education in this case. The central asphericity of this implant causes increased spherical aberration, possibly limiting mesopic visual acuity and contrast sensitivity. The same effect, but for different reasons, is true for multifocal IOLs. The loss of light and the bifocal optics of those lenses may cause night vision disturbances.

The patient has to decide whether he wants to be spectacle independent but might suffer in night driving, or if he wants good vision at all times. In the second option,



which is recommended in our opinion, he should be implanted with aspheric IOLs. Afterward, enhanced progressive reading glasses should be fitted for good near and intermediate vision. As an engineer, he will need both.

**FREDERICO F. MARQUES, MD, PHD;  
AND DANIELA M.V. MARQUES, MD, PHD**

This is a difficult case. We must not promise spectacle independence but rather we must relay appropriate expectations for results after cataract surgery. We would aim to use a technique that removes the cataract and corrects presbyopia in one surgery. The options in this case include pseudophakic monovision, multifocal IOLs, and accommodating IOLs.

It is our obligation to inform the patient about each IOL's advantages and disadvantages. We had a similar case 2 years ago. After extensively explaining monovision and multifocal and accommodating IOLs, the patient chose an aspheric monofocal IOL bilaterally for distance and reading glasses for near. He expressed that he was uncomfortable with the possible disadvantages of multifocal and accommodating IOLs, including halos, glare, and aniseikonia. This demanding patient, despite hating glasses, preferred the monofocal aspheric optical zone IOL. He enjoyed better contrast sensitivity with minimal dysphotopsia and did not bother to use optical correction for near vision.

**ERIK L. MERTENS, MD, FEBOPHTH**

An engineer is certainly not the ideal patient to satisfy easily with premium IOLs. I always use the Dell questionnaire to determine the patient's lifestyle and expectations. This case requires a lot of preoperative chair time to make sure that the patient has realistic expectations after surgery.

This patient can be treated with an accommodating IOL, an aspheric monofocal IOL, or even multifocal IOLs if he accepts losing contrast sensitivity and night vision quality. It depends on how independent he wants to be from glasses.

**TOBIAS H. NEUHANN, MD**

After having the information about the patient's examination and expectations, I have a good basis to start the discussion about IOL selection. With any current IOL designs, even a picky engineer has to make compromises: If he hates glasses but accepts the compromises of an accommodating IOL, the Crystalens HD would be the implant of choice. If he requires 100% emmetropia and accepts monovision, the light adjustable IOL design should give him the highest guarantee to meet his expectations.

**MARK PACKER, MD, FACS**

Conventional wisdom suggests that engineers are not good candidates for multifocal optics because of an inherently perfectionist nature. In this example, the patient's dislike for spectacles may counterbalance his engineering traits; however, the night driving and consequent potential for dysphotopsia complicate the scenario. Additionally, the emmetropic preoperative refraction sets a high bar for achieving an optimal outcome.

I am prepared to spend significant time counseling this patient, describing the various options, and receiving feedback directly from the patient. Solutions may include bilateral aspheric multifocal or accommodating IOLs and possible LASIK enhancement for any residual refractive error. The question will come down to the relative values of spectacle independence and image quality in this patient's mind.

**MAGDA RAU, MD**

The preoperative consultation would be of great importance in this case. If the patient's desire for independence of reading glasses is higher than his fear of the possible optical side effects of glare and halos, I would implant the ReZoom in the dominant eye. If the side effects are still acceptable 4 to 8 weeks after surgery and near vision is satisfactory, I would also implant the ReZoom in the contralateral eye. If the patient is dissatisfied with his near vision, I would implant the diffractive Tecnis IOL in the other eye.

In the case where the patient is more concerned with avoiding glare and halos, I would implant the Akkommodative 1CU (HumanOptics AG, Erlangen, Germany) in the dominant eye. If the patient desires better near vision after 4 weeks, I would calculate the second 1CU in the -0.50 to -1.00 D range.

The other option to improve contrast sensitivity would be implanting an aspheric monofocal IOL with slight monovision. Calculation of the nondominant eye would be approximately -1.00 D.

**MARIE-JOSÉ TASSIGNON, MD, PHD, FEBO**

In this patient, contrast sensitivity and glare are important issues. The patient should be warned that multizonal IOLs decrease contrast sensitivity and increase glare compared with monofocals, but on the other hand, they will require additional reading glasses. Monovision with an interocular difference of -0.50 to -0.75 D for the nondominant eye will reduce the need for reading glasses to situations of long-lasting reading activities only.

**WILLIAM B. TRATTLER, MD**

This patient must be educated that our current presbyopic IOL technology is good but has compromises. The Tetraflex and Crystalens IOLs appear to be the least likely to



cause quality of vision issues at night. Some patients with these IOLs will obtain useful close vision; however, it is not a guarantee. I would, therefore, discuss the benefits and limitations with these technologies. I would also discuss the options of the Tecnis MF and AcrySof IQ Restor +4.0 D, which provide excellent near vision; however, both IOLs have a higher rate of halos than monofocal IOLs.

#### ABHAY R. VASAVADA, MS, FRCS

If the cataracts are visually significant, I would perform microcoaxial phacoemulsification and implant an aspheric monofocal or toric IOL. I would opt for the toric IOL if the keratometric astigmatism is 1.00 D or greater.

For me, this is a case where I would be reluctant to advise a multifocal IOL, because the patient is a night driver; however, I am aware that several multifocal IOLs claim to reduce glare and halos. I would also avoid monovision with a monofocal IOL, as his major activities involve driving at night. My choice of IOL, therefore, would be an aspheric monofocal IOL. I would counsel the patient about the potential problems associated with multifocal IOLs and explain that he may have to accept wearing glasses as a trade-off.

#### ROBERT J. WEINSTOCK, MD

For this patient, I would likely implant the Crystalens bilaterally, with an emmetropic target. Engineers are extremely particular about the quality of their vision and do not tolerate imperfections. Even though the patient will likely need light reading glasses for near work, the Crystalens offers the most spectacle independence and preserves high-quality vision with its monofocal optic and high contrast sensitivity. The patient must be counseled that there is always going to be a compromise, no matter what lens is used, and the Crystalens is best suited for his situation.

**Case Study No. 4: A 70-year-old, 12.00 D myope has worn rigid gas permeable lenses (RGP) with monovision for 30 years. He has 1.50 D cylinder on the keratometry reading. How would you treat this patient?**



(Courtesy of Erik L. Merlens, MD, FEBOPhth)

#### JORGE L. ALIÓ, MD, PhD

Myopic patients with good visual acuity potential—due to their contrast sensitivity loss—are good cases because they simply adapt better to further contrast sensitivity deprivation, which is a typical side effect with multifocal IOLs. Astigmatism correction should be mandatory in this case. A toric IOL implanted through a sub-2-mm incision, such as the toric At.LISA (Carl Zeiss Meditec, Jena, Germany) would be perfect for this case.

#### ROBERTO BELLUCCI, MD

The refraction of this patient should not be changed at all. I would do my best to reproduce the condition that has been satisfying to the patient thus far—even in the case of an impaired macula. Only after obtaining the preoperative refraction with contact lenses will the patient accept any visual impairment.

#### FRANCESCO CARONES, MD

In this case, I would replicate the monovision using two toric IOLs to target the dominant eye at emmetropia and the nondominant at -1.50 D.

#### CHARLES CLAOUÉ, MA (CANTAB), MD, DO, FRCS, FRCOPHTH, FEBO, MAE

This patient has been adapted to monovision for 30 years; he is likely to be happy with monovision with monofocal IOLs. The 1.50 D of corneal astigmatism is easily dealt with using a variety of techniques, including toric IOLs, such as the T-Flex (Rayner Intraocular Lenses, Ltd.) customized toric IOL; limbal relaxing incisions (LRIs); arcuate keratotomy; or on-meridian incisions (if the steep meridian is in the vertical axis).

Incidentally, we are not told the indication for surgery. If the patient has symptomatic cataracts—probable because of his age—then surgery would be advised. If the indication is refractive or contact lens intolerance, then a retinal work-up and modified preoperative counseling is indicated. Irrespective, an IOL with a 360° square edge, such as the SuperFlex Aspheric (Rayner Intraocular Lenses, Ltd.) must be used to minimize PCO, because a capsulotomy in myopic eyes substantially increases the risk of retinal detachment. This IOL is also larger than the standard C-Flex (Rayner Intraocular Lenses, Ltd.), meaning better visualization of the retinal periphery and better adaptation to the typically larger capsular bag. I would advise the patient that for the best outcome he should remove his RGP for a minimum of 4 weeks prior to biometry.

#### JOSE L. GÜELL, MD

In my opinion, there are two choices. The first is to use



a monofocal spheric toric IOL. The second option is to use a monofocal IOL and leave the astigmatism to be corrected later with corneal refractive surgery. In this case, I would aim for plano to -0.25 D in the dominant eye and -1.75 to -2.25 D in the nondominant eye, after consultation with the strabologist.

**OLIVER K. KLAPROTH, DIPL ING(FH);  
AND THOMAS KOHNEN, MD**

In this case, we would recommend keeping the monovision status of the patient as is. The RGPs correct for myopia and astigmatism; a toric IOL will do the same for the patient. The amount of monovision can be examined prior to surgery, and the difference in dioptric powers in both eyes should be the same with the IOLs as it was with the RGPs.

As in nearly every IOL implantation, I would recommend blue-light-filtering optics. The spectral transmission profile of a clear lens does not equal the natural lens. Consequences of this difference in transmission, which we often see in practice, are glare and disturbances in color vision. Furthermore, the risk of retinal detachment is increased in highly myopic patients. Blue-light-filtering IOLs may at least decrease the risk of age-related macular degeneration.

**FREDERICO F. MARQUES, MD, PHD;  
AND DANIELA M.V. MARQUES, MD, PHD**

Patients well adapted to monovision contact lenses should be corrected with pseudophakic monovision. In this particular case, LRIs or a toric IOL is necessary to correct the corneal astigmatism. The latter is more reliable and predictable. The most impressive result with pseudophakic monovision is that, despite residual astigmatism, patients do not require extra surgical procedures or optical corrections.<sup>1</sup> In our experience, patients achieve a distance UCVA of 20/30 or better and a near UCVA of J2 or better.<sup>1</sup>

We recommend using the AcrySof toric IOL (SN60T4 or SN60T5) and planning the dominant eye for distance and the nondominant for near. The SE should be planned for emmetropia and -2.00 D in the dominant and nondominant eyes, respectively. This platform of the AcrySof IOL is stable, with minimal rotation.

The most important step during toric IOL implantation is preoperatively marking the 0° and 180° axes. The most precise method to determine the correct axis is at the slit lamp, finding natural intraocular anatomical marks such as iris defects and iris nevi. Even after cyclo-torsion, the anatomical mark will always be in the same position. The second reliable method of marking the axis is to use a pendulum marker. With the patient seated, he

must focus on a distance target. The latter method is less precise because the mark tends to disappear after irrigation. Because as little as 1° of IOL rotation reduces the astigmatic correction by 3%, it is crucial to be as precise as possible. In our experience, we had one case with an error of 16°. In video analysis, the IOL was placed exactly at the mark. In this particular case, almost 50% of its correction was lost.

1. Marques FF, Marques DMV. Pseudophakic monovision technique with toric IOL. Paper presented at: the American Society of Cataract and Refractive Surgery annual meeting; April 3-8, 2009; San Francisco.

**ERIK L. MERTENS, MD, FEBOPHTH**

Here, we have three options. The first is to implant a multifocal toric IOL, such as the AtLISA toric, in both eyes. Astigmatism is treated efficiently in these cases. Of course, the IOL needs to be placed in the exact axis, but this is obvious when using any kind of astigmatism correction. These IOLs give excellent results in treating astigmatism and even provide reasonably good intermediate vision.

A second option is the AcrySof aspheric toric IOL with monovision. The patient is already used to monovision with his RGPs for 30 years.

A third option would be to implant both eyes with the Crystalens HD because these lenses perform extremely well in higher myopes and in postrefractive surgery cases. The astigmatism can be treated with LRIs or counterincisions, or left as is initially and dealt with a second surgical intervention, such as LASIK or epi-LASIK. In this way, any refractive error can be treated after IOL implantation.

**TOBIAS H. NEUHANN, MD**

Because biometry is still a challenge in this patient group, the treatment regimen must depend on how high the expectations of the patient are. Because the patient has already had good results with monovision, my first choice would be a customized toric IOL. Additionally, we can discuss the difference between toric IOL designs with and without a blue-light filter. STAAR Surgical (Monrovia, California); Rayner Intraocular Lenses, Ltd.; Carl Zeiss Meditec; and Alcon Laboratories, Inc.; all make toric IOLs.

Nevertheless, we must inform every patient that with toric IOLs, the postoperative refraction does not always reach emmetropia. Why? With most IOL designs, because we are unable to perform the IOL calculation ourselves, we must rely on the IOL calculation from the companies. Sometimes, postoperative fine-tuning with the excimer laser is necessary.

A newer option is the Calhoun Vision's LAL. In these patients, postoperative fine-tuning is essential.



## MARK PACKER, MD, FACS

I tend to prefer the Crystalens HD in high myopia because I have obtained more consistent results in terms of minimal postoperative refractive error and decreased need for reading glasses. In this case, however, the patient's history of successful monovision leads me to believe that this option will best serve him. Additionally, LRIs can easily reduce the keratometric cylinder to 0.50 D or less.

Intraoperative wavefront aberrometry serves as an adjunct to ensure full correction of the astigmatism. It is important to measure the corneal topography after the patient has been out of contact lenses for at least 3 weeks. A careful vitreoretinal examination is warranted, although it is likely that a 70-year-old has already had posterior vitreous detachments and thus less risk of retinal complication. A CTR should be considered in eyes with an axial length of more than 26 mm if there are signs of capsular instability during the capsulorrhexis.

## MAGDA RAU, MD

Because the patient has been satisfied with RGPs for 30 years, I would implant a monofocal toric IOL in both eyes, retaining the monovision in the same way as with the RGPs. I would be sure to keep the same eye for distance and the same eye for near vision as previously determined with the RGPs.

## MARIE-JOSÉ TASSIGNON, MD, PhD, FEBO

In this patient, monovision can be maintained. I would propose the BIL lens. Using the SRK-T formula for high myopia of axial origin, the calculation may induce a slight hyperopic shift. It is therefore important to aim at -1.00 to -1.50 D.

## WILLIAM B. TRATTLER, MD

I would first perform preoperative corneal topography to confirm that the astigmatism is symmetrical. This patient must be educated that he may not see as well after cataract surgery as he saw with RGPs prior to the cataract's development.

I would recommend aspheric toric IOLs with either mini-monovision or full monovision, depending on the patient's previous contact lens strategy prior to his development of visually significant cataracts. I would optimize the orientation of the toric IOLs by using intraoperative aberrometry (ORange; Wavetec Vision Systems, Inc., Aliso Viejo, California).

## ABHAY R. VASAVADA, MS, FRCS

Here is a person who has always been myopic and has enjoyed good vision for near and distance with monovision contact lenses. Considering that he has 1.50 D of

keratometric astigmatism, he is a good candidate for bilateral toric IOLs. Because the patient is already accustomed to monovision with contact lenses, it is relatively easy to explain monovision with toric IOLs. The dominant eye would be kept emmetropic for distance and the other eye would be kept myopic by approximately 2.00 D. This way, the patient will enjoy the benefits of monovision and will be practically free of glasses for both near and distance vision because the toric IOL neutralizes the astigmatism.

## ROBERT J. WEINSTOCK, MD

With the patient's long-standing history of successful monovision use in contacts, I would stick with monovision-targeting implants. I prefer an aspheric monofocal implant such as the Akreos or Hoya's monofocal implant. Because this patient has a visually significant amount of corneal astigmatism, he will need it corrected. For anything under 2.00 D on the cornea, I prefer to do LRIs. This patient will require two or three incisions, depending on the axis of astigmatism. I would also use the ORange intraoperative aberrometer to guide the astigmatism correction and confirm its reduction and the monovision targeting.

**Case Study No. 5: A 52-year-old nearly emmetropic stockbroker loves to play golf. He currently has clear lenses and wants to be spectacle independent at all costs. How would you treat this patient?**

## JORGE L. ALIÓ, MD, PhD

A 52-year-old emmetrope will not be happy with any of the available options at this moment. The personality of this patient, because he is active and plays sports, makes it clear that binocularity is required. Monovision would probably not be a good option in this case.

I would not advise intraocular surgery in this case but rather corneal surgery with presby-LASIK (PresbyMax; Schwind eye-tech-solutions, Kleinostheim, Germany). PresbyMax is a pupil-dependent procedure that will leave the patient with binocularity for far and near and spectacle independence for most of the patient's normal activities within intermediate and far vision. This is a good example of the potential applications of corneal multifocal surgery.

## ROBERTO BELLUCCI, MD

This patient will probably benefit from LASIK.






Figure 9. The M-Flex has a 360° square-edge design.

Emmetropia will allow him to play golf without glasses, also increasing near vision without glasses. Ideally, I would look for a refractive outcome of -0.25 D.

#### FRANCESCO CARONES, MD

I would not perform surgery on this patient. Honestly, I do not think any of the technology available at present would fully satisfy all of this patient's needs.

#### CHARLES CLAOUÉ, MA(CANTAB), MD, DO, FRCS, FRCOPHTH, FEBO, MAE

The patient's desire for spectacle independence is a good indication for a refractive solution. The options are (1) monofocal IOLs set for monovision or (2) multifocal IOLs. My experience is that ardent golfers want to maintain their stereopsis, making monovision less attractive. Although monovision is often a good solution, almost all patients laugh when it is presented. Patients have a hard time believing that the advantages of binocular vision could be compromised.

In counseling this patient, I would advise serious consideration of simultaneous bilateral lens surgery (to minimize anisometropic symptoms) using a modern multifocal IOL with a 360° square edge, such as the M-Flex (Figure 9). Emmetropic patients are the most demanding group. I would be prepared to do an IOL exchange at an early stage if either eye is not emmetropic postoperatively.

#### JOSE L. GÜELL, MD

Assuming that the patient and I, coordinating options and expectations, decide to undergo surgery, I would treat this 52-year-old patient with the same approach as the 68-year-old patient in case No. 1 (ie, blended monovision). In this case, it is extremely important to stress to the patient that he will commonly use near vision correction.

#### OLIVER K. KLAPROTH, DIPL ING(FH); AND THOMAS KOHNEN, MD

It will be hard to satisfy this patient with any kind of surgery. Possible options include the implantation of accommodating, multifocal, or aspheric IOLs with monovision. In my experience, these patients are treated best with multifocal soft contact lenses (or progressive glasses), as long as cataract formation does not occur. A surgical intervention is not recommended yet.

#### FREDERICO F. MARQUES, MD, PHD; AND DANIELA M.V. MARQUES, MD, PHD

Unfortunately, this is an easy case for turning a relatively happy patient into a dissatisfied one. Because the patient still has clear lenses—and probably a healthy macula—the quality of his visual acuity is high. No IOL can generate the ideal characteristics of our natural optical system.

In this case, I would perform a monovision contact lens trial and analyze the patient's satisfaction during daily as well as leisure activities (eg, golf). Sometimes the patient does not want further treatment and is happy with contact lenses. If the patient is happy and wants to be corrected surgically, he is a good candidate for pseudophakic monovision; otherwise, we would not recommend surgery. We do not recommend multifocal IOLs.

We had a similar case of a 50-year-old emmetropic female with the desire of eliminating spectacles. We planned surgery in both eyes, implanting the Tecnis ZM in her dominant eye. On the first postoperative day, she was unhappy with a UCVA of 20/30 for distance and J3 for near. After 7 days, her UCVA did not improve, and the residual refractive error was 0.75 D sphere. We decided to perform surgery and captured only the optical zone to completely eliminate the refractive error. After 1 week, her UCVA was 20/20 (plano) for distance and J1 for near; however, she was not completely happy. At 3 months, she continued to complain of blurred vision with minimal PCO (1+) and UCVA of 20/20 and J1. The Tecnis ZM is sensitive to opacities, and we decided to perform a Nd:YAG capsulotomy, resulting in UCVA 20/20 and J1 at 1 month. The patient was not completely satisfied, complaining that her quality of the image in the fellow eye (phakic eye) was better. She declined surgery in the second eye.

#### ERIK L. MERTENS, MD, FEBOPHTH

This is a tricky patient because he is still young and has excellent distance vision and clear lenses. Every surgery will probably leave him with worse distance vision than he had preoperatively. Preoperative counseling is always extremely important, specifically in these patients. If he





**Figure 10.** Five circular rings are created on the corneal stroma with the femtosecond laser, without opening corneal tissue.

understands that in order to give him good distance vision, excellent near vision, and acceptable intermediate vision he must (1) give up some distance vision and (2) accept a decrease in night vision, he is a good candidate for a low-add aspheric Restor IOL.

#### TOBIAS H. NEUHANN, MD

If surgical costs are not an issue and nearly emmetropic refers to a current refraction between 0.50 and 1.00 D sphere, I would recommend IntraCOR (Technolas Perfect Vision, Heidelberg, Germany; Figure 10). This procedure would give him the option to see near and far after 20 seconds of treatment per eye. If cataract starts to develop later on, the IntraCOR investment may be again used for near vision when implanting a customized monofocal aspheric IOL.

#### MARK PACKER, MD, FACS

The Tecnis MF offers the highest rate of spectacle independence without much cost in terms of downside risk. At 1 year, 96.4% of patients enrolled in the US FDA-monitored clinical investigation said they were functioning comfortably at the distance and near ranges without glasses. A total of 93.8% said they were functioning comfortably at intermediate range without glasses.<sup>1</sup> Only 10.4% complained of moderate to severe halos, and 11.2% noted difficulty with vision.

1. Summary of Safety and Effectiveness Data, Tecnis Multifocal Intraocular Lens. US Food and Drug Administration Website. Available at: <http://www.fda.gov/cdrh/pdf/8/P080010b.pdf>. Accessed July 17, 2009.

#### MAGDA RAU, MD

When male patients request a clear lens exchange after a detailed consultation, I initially implant the refractive

ReZoom multifocal IOL in the dominant eye, followed by an exam 4 to 8 weeks later. If the patient is satisfied with the multifocal IOL, I continue with the same type of lens in his contralateral eye. If the patient requires slight improvement in near vision, I calculate the refractive multifocal IOL at -0.50 D.

If the patient were female, I would have begun with the nondominant eye and implanted a diffractive Tecnis IOL or a refractive lens with a central zone for near vision, such as the MF4 (Carl Zeiss Meditec). If the patient is still satisfied 4 to 8 weeks later, I continue with the same IOL. However, if the patient prefers better visual acuity in the intermediate to far range, I combine the Tecnis or MF4 with a refractive ReZoom lens.

In the case of this stockbroker who enjoys golfing, I would start by implanting the dominant eye with the ReZoom. Implantation of the multifocal IOL in the other eye would not follow until the patient reaches satisfaction with his first operated eye. Another option would be conductive keratoplasty.

#### MARIE-JOSÉ TASSIGNON, MD, PHD, FEBO

If my instincts are right, I would think that this patient is not very demanding about the quality of the image. My proposition would be to combine the monofocal BIL, aimed at emmetropia, with accommodating supplementary lenses in both eyes. I would perform the bilateral operation simultaneously.

#### WILLIAM B. TRATTLER, MD

I would not recommend intraocular surgery for this patient. I would have this patient try a contact lens in the nondominant eye, setting it for near. If this provides satisfactory vision, I would discuss the options of continuing with a contact lens versus laser vision correction for near in that eye.

#### ABHAY R. VASAVADA, MS, FRCS

The long-term effects of refractive lens exchange are not yet known in terms of PCO and other complications. For these reasons, I do not perform refractive lens exchange, and I would first advise the patient to avoid surgery as long as possible.

But since, in this specific clinical scenario, the patient wants to be spectacle independent at all costs, my advice is as follows: Opt for refractive lens exchange with a presbyopia-correcting IOL, such as the AcrySof IQ Restor +3.0 D. His visual demands require that he have good vision both for near and distance. This IOL provides excellent distance and near acuity and reasonably good vision for intermediate distance.

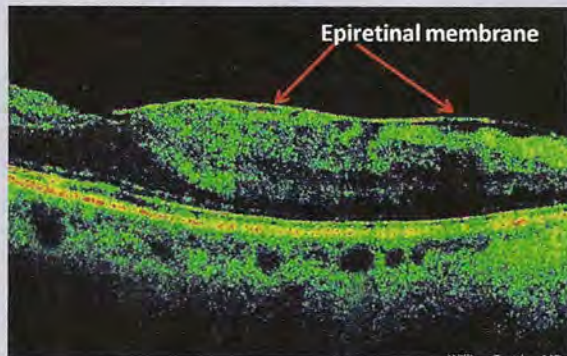


**ROBERT J. WEINSTOCK, MD**

This is a challenging patient. With no cataracts present, he would probably be dissatisfied with the reduced contrast sensitivity and nighttime visual disturbances found with multifocal IOLs. He would also be unimpressed with the Crystalens because although it offers good day and night quality of vision at distance and mid-zone targets, it will still leave the patient using reading glasses for heavy reading.

This leaves the only viable option as monovision. A contact lens monovision should be done to ensure it can perform well for the patient and confirm that he tolerates the anisometropia. For a right-handed golfer, it is best to make the right eye for near. At 52 years old, a clear lens extraction would be preferable over LASIK.

**Case Study No. 6: The patient's OCT scan reveals an epiretinal membrane (ERM). How would you treat this patient?**



(Courtesy of William B. Trattler, MD)

**JORGE L. ALIÓ, MD, PHD**

Neither multifocal nor accommodating IOLs will work well with the visual deprivation caused by ERMs. If the membrane is significant, macular surgery is necessary. Outcomes after cataract surgery cannot be guaranteed; performing this operation would make the patient's life more complicated because macular problems do not fit well with optical multifocality.

**ROBERTO BELLUCCI, MD**

With a positive Amsler test, combined microincision cataract surgery and 25-gauge sutureless pars plana vitrectomy with the Millennium (Bausch & Lomb) is my routine approach. This is usually done on an outpatient basis, under local anesthesia. If the Amsler test is negative, only cataract surgery is performed at first. Only patients younger than 45 years with clear lenses are offered vitrectomy alone.

**FRANCESCO CARONES, MD**

I would keep track of the evolution of the ERM by OCT-

scanning laser ophthalmoscopy. In case of an evolution that reduces BCVA, I recommend vitreoretinal surgery. However, I would not remove the lens if it is still clear and transparent.

**CHARLES CLAOUÉ, MA(CANTAB), MD, DO, FRCS, FRCOPHTH, FEBO, MAE**

First, you must determine if the ERM can be visualized following pupil mydriasis. If not, the lens is presumably so opaque that cataract surgery is indicated before you can even assess whether the ERM is visually significant. Second, check if the ERM is located on the central fovea. If not, it may be asymptomatic.

It may not be entirely possible to determine whether lens opacity or ERM is the main cause of visual symptoms preoperatively; however, I find it helpful to ask patients whether their vision is more distorted versus misty, the former implicating the ERM as the main component. I would not allow an ERM to dissuade me from lens surgery; however, preoperative counseling must be modified and patient expectations modulated.

**JOSE L. GÜELL, MD**

ERMs will effect the operation if visual acuity is clearly diminished and the patient either has metamorphobia or the foveal profile on OCT is clearly distorted. The cataract will be operated with similar consideration as previous patients in these case studies. Multifocality is not recommended, both for patient and vitreoretinal surgeon visualization.

**OLIVER K. KLAPROTH, DIPL ING(FH); AND THOMAS KOHNEN, MD**

In case of cataract treatment for this patient, I would choose a monofocal aspheric blue-light-filtering IOL. Target refraction would be approximately -0.50 to -0.75 D.

**FREDERICO F. MARQUES, MD, PHD; AND DANIELA M.V. MARQUES, MD, PHD**

In cases with macular disorders, we should always use IOLs with a monofocal optical zone. These IOLs boast better image quality, which is crucial in this case due to the strong possibility of future surgical peeling of the ERM. Use of multifocal IOLs is highly contraindicated because the macula must be in perfect condition to capture the images produced by the IOL's multiple focal points.

Another important consideration is the IOL material. Because the patient is at high risk for retinal surgery, we should avoid implanting a silicone IOL, which would react negatively with silicone oil in the vitreous cavity used in the case of future retinal detachment. A hydrophobic acrylic IOL is preferred in this case. We would suggest a toric IOL if there is some corneal astigmatism or an accommodating IOL to restore some near vision.



**ERIK L. MERTENS, MD, FEBOPHTH**

I would send this patient to a retinal specialist to find out how serious the ERM is and if peeling of the membrane is necessary. According to the quality of the macula, I would make my choice regarding the IOL to be implanted.

**TOBIAS H. NEUHANN, MD**

In this case, I would measure the complete aberration of the cornea—not only the aberration of the surface—and implant a customized monofocal aspheric IOL design.

It is important to intensively discuss the possibility of reduced postoperative visual results with the patient. Follow-up in the postoperative phase must include OCT and testing the reaction of the ERM. If necessary, offer surgery for the ERM.

**MARK PACKER, MD, FACS**

The key to this situation is preoperative recognition and counseling regarding any expected limitation of postoperative acuity or image quality. If the membrane is not bad enough or not amenable to peeling, then its effects will continue indefinitely. A multifocal IOL is not a good choice in this case, and even the result with an accommodating IOL may be disappointing. Nevertheless, I would not rule out the latter if expectations are set appropriately.

**MAGDA RAU, MD**

I would send this patient to an experienced posterior segment surgeon. If the patient has a cataract, I would ensure that preoperative counseling included advice on limited postoperative visual acuity and quality of vision. Consideration for retinal operations, to achieve better visual acuity, is also important. I would implant a monofocal IOL with a blue filter to protect the retina, such as those available from Hoya, Dr. Schmidt Intraocularlinsen GmbH (St. Augustin, Germany), and Polytech Ophthalmologie GmbH (Vienna, Austria).

**MARIE-JOSÉ TASSIGNON, MD, PHD, FEBO**

A combined cataract-vitrectomy for macular peeling would be my proposal. Prior to surgery, microperimetry will reveal the presence of preexisting scotomas or focal decreased retinal sensitivity. Multifocal IOLs should not be proposed in the presence of impaired macular function.

**WILLIAM B. TRATTLER, MD**

For patients with cataracts who have preexisting ERMs, I would not offer a presbyopia-correcting IOL because the risk of an unsatisfactory result is relatively high.

The ERM can reduce the quality of vision postoperatively. It also places the patient at increased risk of cystoid macular edema (CME). I would, therefore, discuss a mini-

monovision strategy with the patient and recommend pre- and postoperative NSAID drops for 6 to 8 weeks to reduce the risk of CME.

**ABHAY R. VASAVADA, MS, FRCS**

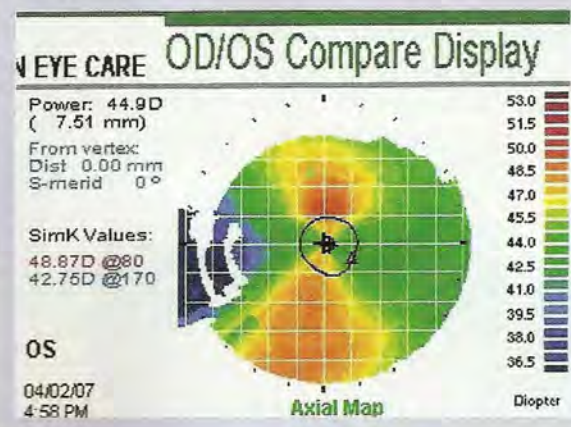
If the patient's lenses are clear, I would refer him to a retinal surgeon for management of the ERM. If the patient has visually significant cataract, I would perform phacoemulsification followed by management of the ERM as the second stage. My choice of IOL here would be an aspheric monofocal IOL.

**ROBERT J. WEINSTOCK, MD**

If I see a patient with cataracts and the exam reveals a dull foveal reflex or an ERM, I always get an OCT. If the OCT shows normal retinal thickness, I proceed with the cataract surgery but I warn the patient that he may develop some transient or lasting macular edema and may even need to see a retinal specialist down the road for treatment.

I avoid multifocal IOLs in these patients; however, I will consider the Crystalens or monovision. All patients receive Pred Forte (prednisolone acetate; Allergan, Inc., Irvine, California) four times a day for 4 weeks then twice a day for 2 weeks. They also get Xibrom (bromfenac; ISTA Pharmaceuticals, Irvine, California) b.i.d for 6 weeks. If the patient has any degree of macular edema on the OCT (ie, macular thickness greater than 280  $\mu$ m), I will a retina consult prior the cataract surgery.

**Case Study No. 7: A cataract patient with 6.00 D of astigmatism on topography is scheduled for surgery. How would you treat this patient?**



(Courtesy of William B. Trattler, MD)

**JORGE L. ALIÓ, MD, PHD**

I am fully in favor of intraocular correction of astigmatism during cataract surgery. Toric IOLs are the best



option; results in my experience have been perfect. I use microincision cataract surgery, which fits perfectly with the concept of toric IOLs because sub-2-mm incisions do not change corneal astigmatism. It converts the surgery to more precise and reliable terms for refractive correction. My choice would be the Acri.Comfort toric monofocal IOL (Carl Zeiss Meditec) or a toric At.LISA if the case fits well for a multifocal IOL implantation.

### ROBERTO BELLUCCI, MD

A toric IOL is the obvious choice, but even if we select the Zeiss toric IOL, providing the equivalent of 6.00 D of toricity, some residual astigmatism should be anticipated by the patient. Postoperatively, LASIK can be an option to correct this eye completely.

### FRANCESCO CARONES, MD

Given the amount of astigmatism, I would recommend a toric in-the-bag IOL. I would not perform LRIs to correct some of the preexisting astigmatism at the time of cataract extraction, and I would not plan to correct the residual astigmatism at a later stage using the excimer laser, simply because the correction of astigmatism with toric IOLs is more predictable and safer than other options.

### CHARLES CLAOUÉ, MA(CANTAB), MD, DO, FRCS, FRCOPHTH, FEBO, MAE

I would want to see the topography to determine if this patient has keratoconus. If so, corneal incisions are contraindicated and toric IOLs are unpredictable. In the absence of keratoconus, it is possible to use a monofocal IOL with arcuate keratomies at the 7-mm optical zone to treat 6.00 D cylinder. The procedure may be foreign for noncorneal-trained surgeons, and the predictability is best described as moderate. LRI nomograms occasionally suggest that 6.00 D of astigmatic correction is possible; however, my experience is that LRIs have greater unpredictability because of the role of vascular healing. I believe that LRIs are not appropriate for more than 2.00 to 3.00 D of corneal astigmatism. Thus, this patient is potentially a recipient of a toric IOL.

Presumably, this patient has always had corneal astigmatism and may be fully adapted to wearing spectacles—such patients occasionally wear plano spectacles if rendered emmetropic. This must be clarified preoperatively; not everyone wants to be emmetropic. If this patient wants to be emmetropic, I would preorder a T-Flex customized toric IOL; if the patient is motivated to be spectacle independent, I would opt for the toric multifocal aspheric M-Flex T.

### JOSE L. GÜELL, MD

After confirming on the topography that the astigmatism is regular and thus stable, I would possibly use a toric aspheric IOL (T-Flex) with considerations similar to the other patients in these cases, regarding final refraction.

### OLIVER K. KLAPROTH, DIPL ING(FH); AND THOMAS KOHNEN, MD

In this case, it can easily be decided that a customized toric IOL would be the best solution for the patient. The existing ametropia and the astigmatism, as well as the cataract, are treated in one step with the toric IOL. All available toric IOLs show superior rotational stability and thus excellent correction of refractive errors.

### FREDERICO F. MARQUES, MD, PHD; AND DANIELA M.V. MARQUES, MD, PHD

This is a wonderful situation to use toric IOL with good results. In this case, we would recommend targeting pseudophakic monovision with the AcrySof SN60T9. Theoretically, this IOL corrects astigmatism up to 4.11 D at the corneal plane; the residual astigmatism may be reduced with a LRI if desired. However, most patients with high corneal astigmatism are extremely satisfied, even in the presence of some residual astigmatism.<sup>1</sup> In our case series, no patients required extra surgical procedures or optical corrections after toric IOL implantation. All patients achieved a distance UCVA of 20/30 or better and near UCVA of J2 or better.<sup>1</sup>

1. Marques FF, Marques DMV. Pseudophakic monovision technique with toric IOL. Paper presented at: American Society of Cataract and Refractive Surgery annual meeting; April 3-8, 2009; San Francisco.

### ERIK L. MERTENS, MD, FEBOPHTH

There are two possible plans of action in this case: (1) the AcrySof Toric IOL with LRIs, a counterincision, or postoperative LASIK or epi-LASIK or (2) the Acri.Comfort toric IOL, which will be custom made to correct the full cylinder. A manufacturing period of up to 60 days must be explained to the patient if using the Acri.Comfort.

### TOBIAS H. NEUHANN, MD

This patient must inform the surgeon of his expectations after surgery. If he is not too old (younger than 90 years) and has a healthy cornea and macula, we can discuss three options: (1) a customized monofocal aspheric IOL with distance and reading glasses, which is not a sophisticated option; (2) a customized monofocal aspheric toric or bitoric IOL with reading glasses or monovision, and, my personal favorite; (3) a customized multifocal aspheric bitoric IOL (At.LISA 466TD).

Postoperative fine-tuning with the excimer or fem-



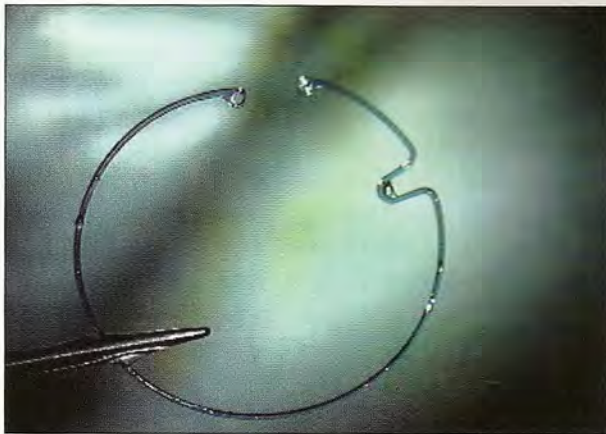

Figure 11. The Acri.Clip is a notched capsular tension ring.

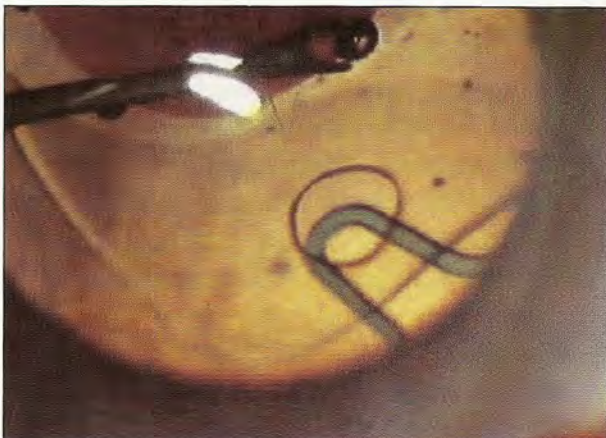

Figure 13. Intraoperative clipped toric IOL, with no chance to rotate postoperatively.

to second laser, if necessary, must also be discussed.

Although there are reports of axis rotation with each toric IOL design, I prefer to use a special notched CTR (Acri.Clip; Carl Zeiss Meditec; Figures 13-15), implanted after the toric IOL to secure the IOL in place.

#### MARK PACKER, MD, FACS

To correct 6.00 D of corneal cylinder in the United States will require both a toric IOL and a LRI, and perhaps also a LASIK enhancement. If this patient wants a multifocal IOL, then I will perform maximal LRIs at the time of cataract surgery and plan on LASIK once the refraction stabilizes at about 6 weeks.

#### MAGDA RAU, MD

My first choice would be a capsular-bag-fixated three-piece toric IOL. The model MS 6116 TU (HumanOptics AG) is, in my opinion, the best choice for patients with high cylinder. This three-piece, silicone IOL produces an

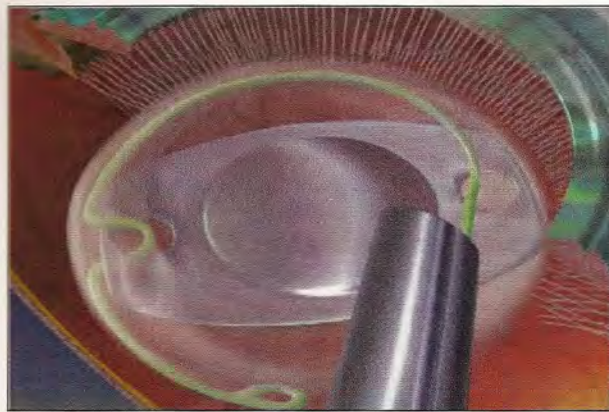


Figure 12. The clip grabs the haptic on the hole while one half of the clip is in front and the second half is behind the haptic.

accommodative effect of 1.80 to 0.45 D and has shown the best rotational stability of any IOL I have worked with. It also has an extremely low PCO rate because of its 360° sharp optic edge. Although at first glance the MS 6116 TU—with its Z-haptics—looks difficult to implant, it is actually not a problem to insert safely and without hassle.

If the patient would like to be independent from reading glasses, I would perform bioptics. I would start with implantation of a multifocal IOL and after 8 weeks I would perform surface ablation (LASEK) to correct the astigmatism and spherical postoperative ametropia if any is present. Multifocal IOLs are generally known to cause loss of contrast sensitivity, with LASIK furthering the loss. This combination could present a significant problem for the patient while driving at night. For this reason, I prefer bioptics with LASEK.

#### MARIE-JOSÉ TASSIGNON, MD, PHD, FEBO

In patients with high astigmatism, a customized toric BIL is ordered. The BIL technique allows use of high-powered astigmatism implants because, inherent to this technique, the rotational stability is reliable.

#### WILLIAM B. TRATTLER, MD

Patients with this degree of astigmatism are a challenge. In the United States, we have only one option for toric IOLs, and the maximum correction is 2.00 D of astigmatism. I will offer to further reduce patient's astigmatism with intraoperative LRIs.

In this type of case, I have found that intraoperative wavefront aberrometry with the ORange system helps fine tune the orientation of the toric IOL, and then I can use it to determine the effect of the LRIs. After taking my ORange readings, I would be able to decide whether



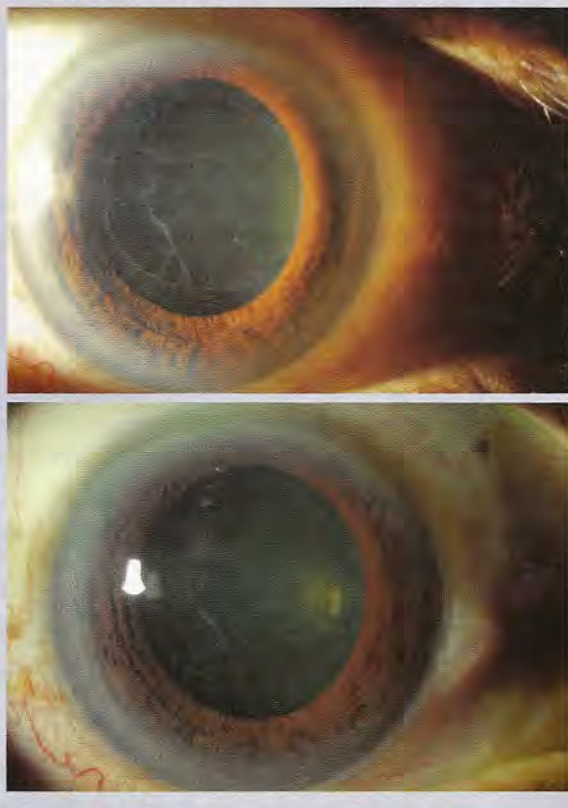
enhancement of the LRIs is required. Lastly, with this degree of astigmatism, I would also inform the patient that most likely he will need PRK at 3 to 4 months post-operatively to reduce any residual refractive error.

## ABHAY R. VASAVADA, MS, FRCS

I would use a combination of the highest available cylinder model of the AcrySof toric IOL and LRIs to reduce astigmatism as much as possible. In my experience, combining toric IOLs with LRIs to treat the residual astigmatism is successful in eliminating most, if not all, of the astigmatism. Also, it is equally important to counsel the patient about the possibility that the eye could be amblyopic, and therefore visual recovery after surgery could be suboptimal.

(Courtesy of William B. Trattler, MD)

### Case Study No. 8: What is your treatment protocol in the presence of pseudoexfoliation?



## JORGE L. ALIÓ, MD, PhD

Pseudoexfoliation is difficult because it often leads to intraoperative complications and is frequently followed by PCO. If complications arise in the first eye due to decentration of the multifocal IOL or Crystalens, the second eye cannot be implanted with this IOL. If the patient also has pseudoexfoliation in his second eye, then we

really have a difficult problem to solve. This is why I prefer to use monofocal IOLs as an approach, preceded by adequate discussion about monovision versus the risk of the other possibilities.

At the time of surgery, I would have available both in-the-bag and in-the-sulcus IOL powers. For in-the-bag implantation, I would use the aspheric Acri.Smart 46LC (Carl Zeiss Meditec) associated with a CTR. For sulcus implantation, my favorite IOL is the traditional Alcon MA60.

## ROBERTO BELLUCCI, MD

Pseudoexfoliation requires a lens that is able to mimic the shape and size of the capsular bag equator, avoiding both bag ovalization and late bag contraction. Polyvinylidene haptics have been my preferred choice; however, polymide haptics also give good results in my experience. One-piece lenses like the AcrySof, Tecnis 1-Piece, or the Akreos can also be used, especially the last one, which does not pull on the bag equator. With advanced pseudoexfoliation, I always use a CTR.

## CHARLES CLAOUÉ, MA(CANTAB), MD, DO, FRCS, FRCOPHTH, FEBO, MAE

Pseudoexfoliation continues to be a great challenge. We have long recognized the risk of surgical complications linked to small pupils and/or zonular fragility. Surgeons have a large variety of strategies for dealing with small pupils. My own preferred strategies are either the Malyugin pupil expander (MicroSurgical Technology, Redmond, Washington), or, if cost limitations apply, multiple tiny sphincterotomies.

Although many modern IOLs have been shown to center exceptionally well, I would not be comfortable implanting an IOL without a CTR in cases of pseudoexfoliation. Nevertheless, such patients may return years later with a dislocated capsular bag/CTR/IOL complex, and they can pose formidable surgical challenges. To avoid excessive stretching of the capsular bag with an oversized IOL, I would choose an IOL specifically designed to fit the capsular dimensions such as the C-Flex Aspheric, which has a maximum diameter of 12 mm.

I would only use an IOL with a 360° square edge to minimize PCO and the need for a Nd:YAG capsulotomy, which would further weaken the zonulocapsular diaphragm. I remain amazed that there are still manufacturers who offer IOLs without a 360° square edge in the 21st century.

Would I use a toric or multifocal IOL? If the surgery is routine, I would be happy to implant a multifocal IOL.



However, if the surgery is problematic, I would think carefully before sulcus placement because of the unpredictability of the residual zonulocapsular diaphragm. Would I be happy with an anterior chamber IOL? Given the frequency of secondary open-angle glaucoma in these eyes, probably not. In the absence of adequate capsular or sulcus support, I would leave the eye aphakic for a short period and then implant an Artisan iris-supported aphakic IOL (Ophtec BV, Groningen, Netherlands). However, my planned implants would be a CTR and a C-Flex Aspheric IOL.

#### JOSE L. GÜELL, MD

Apart from the standard cataract surgery considerations—that depend on lens hardness and zonule status—generally speaking, I would use a sulcus-designed IOL to be implanted in the sulcus.

#### OLIVER K. KLAPROTH, DIPL ING(FH); AND THOMAS KOHNEN, MD

Standard cataract treatment with monofocal IOLs is indicated. Pseudoexfoliation can cause capsular contraction and IOL decentration. Accommodating and multifocal IOLs should be selected with care.

#### FREDERICO F. MARQUES, MD, PhD; AND DANIELA M.V. MARQUES, MD, PhD

Patients with pseudoexfoliation have greater chances for intraocular complications due to poor dilation and zonular dialysis. Therefore, careful preoperative examination is necessary to find any sign of zonular damage, such as phacodonesis, iridodonesis, and vitreous prolapse. The surgeon must also look for more subtle signs, including of a visible lens equator in extreme downgaze, superior displacement of the fetal nucleus, an asymmetric iridolenticular gap, and signs of focal crystalline lens retraction due to the zonular absence.<sup>1</sup>

Before the start of surgery, the staff must double check that iris retractors, CTRs, and Prolene sutures (10-0 or 9-0 mm) are on hand. The surgeon must be prepared to perform iris fixation, scleral wall fixation, or even suturing the CTR or modified CTR to the scleral wall. During surgery, any further damage to the zonules should be avoided by using low parameters, such as infusion rate. This will generate less intraocular turbulence and more surgical control.

During capsulorrhexis, it is not uncommon to see anterior capsule wrinkles revealing focal zonular weakness. Gentle maneuvers are necessary during phacoemul-

# FIRST

Sterimedix is the first choice for single-use I/A handpieces that give you the quality and precision of a re-usable instrument - in a disposable.

Our latest I/A handpieces add to an already impressive range of disposable instruments, designed to meet the highest demands of ophthalmic surgeons today.

**STERIMEDIX**

single-use ophthalmic innovations

[www.sterimedix.com](http://www.sterimedix.com)

for our full product range

or call: +44 (0)1527 501480



sification; in cases of a hard nucleus, we recommend enlarging the capsulorrhexis to reduce trauma to the zonules. Irrigation/aspiration must also be done with extreme care because these are often loose capsular bags. In such cases, we proceed with a dry technique using a 27-gauge cannula to aspirate the remaining cortex followed by the insertion of a CTR.

IOL insertion should be done carefully inside the capsular bag, and special attention should be paid in the case of a three-piece design because the leading haptic may tear the posterior capsule during insertion. Thus, a one-piece IOL, such as the Tecnis 1-Piece or AcrySof IQ, make this step easier.

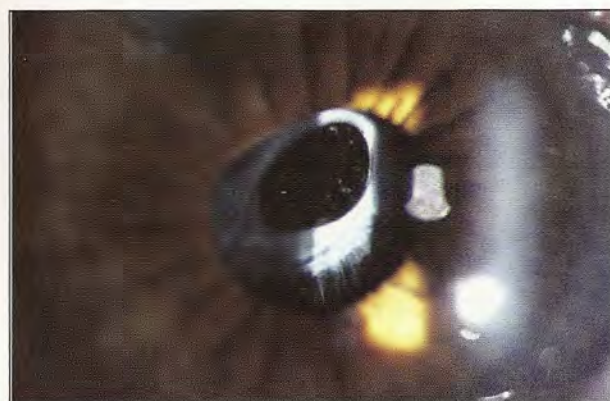
1. Marques DM, Marques FF, Osher RH. Subtle signs of zonular damage. *J Cataract Refract Surg.* 2004;30(6):1295-1299.

**ERIK L. MERTENS, MD, FEBOPHTH**

The cases of pseudoexfoliation we operate on generally are not so severe. In these cases, we implant all types of IOLs except silicone lenses. In case of zonular instability, a CTR is implanted.

**TOBIAS H. NEUHANN, MD**

During the preoperative discussion, I undoubtedly inform the patient about his increased risk for getting a poor postoperative result. Nevertheless, the presence of



**Figure 14. Pseudoexfoliation and capsular contraction syndrome with a silicone IOL.**

pseudoexfoliation will not limit the choice of the IOL designs we discuss; however, it does limit the IOL material.

I exclude PMMA, hydroxyethylmethacrylate (HEMA), and silicone IOLs because of a higher incidence of capsular contraction syndrome (Figure 14) with these materials. Hydrophilic and hydrophobic IOL materials have a higher adhesiveness to the lens capsule, which will reduce the risk of capsular contraction syndrome significantly.

A CTR is often used in these surgeries without compromising the IOL design.

# NOW AVAILABLE IN HARDBACK... CATARACT SURGERY TODAY

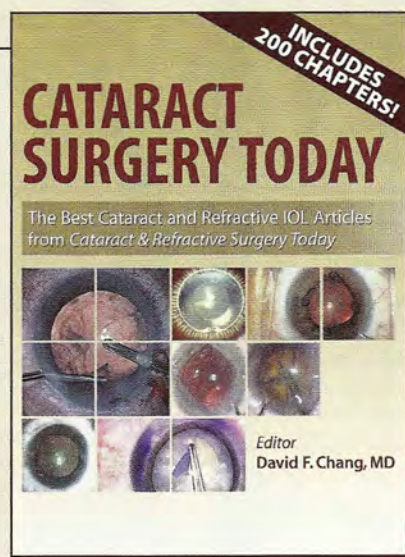
The Best Cataract and Refractive IOL Articles  
from *Cataract & Refractive Surgery Today*



David F. Chang, MD

This comprehensive textbook is a compilation of 200 of the best cataract and IOL articles published in *Cataract & Refractive Surgery Today* as selected by editor David F. Chang, MD. Covering topics such as strategies for complicated cases, endophthalmitis prophylaxis, new surgical technologies, complications, and both monofocal and refractive IOLs, this 430-page textbook is authored by the most prominent names in the fields of cataract and refractive surgery.

Please visit <http://eyetube.net/store> to place your order and view the table of contents and sample chapters.





**MARK PACKER, MD, FACS**

I do not use silicone in the presence of pseudoexfoliation due to the enhanced anterior capsular opacification and potential phimosis. I often use a CTR, but not always, as many of these go smoothly without a ring. I implant multifocal IOLs in these patients if they desire spectacle independence.

**MAGDA RAU, MD**

The presence of pseudoexfoliation always indicates an increased risk of capsular rupture, with or without loss of the nucleus in the vitreous. To avoid these complications, we try to obtain maximal mydriasis preoperatively. If the mydriatic drops do not adequately widen the pupil, I apply intracameral epinephrine. If the eye does not respond, I use an iris spreader to enlarge the pupil. If the cataract is mature, I use purified Trypan blue (Monoblue 0.055%; Arcad Ophtha, Launac, France) to make the capsule visible; the capsulorrhexis should be at least 5 mm. I would perform microcoaxial phaco with a 2-mm incision. The more stable the anterior chamber is during surgery, the lower the risk of complications. I use the CTR if there are signs of zonular weakness. Implantation of the BioVue 3TM (Aaren Scientific, Inc., Ontario, California), a heparin-surface-modified IOL, decreases the risk of posterior capsular fibrosis.

**MARIE-JOSÉ TASSIGNON, MD, PhD, FEBO**

If there is no preop phacodonesis, the BIL is best implanted with an endocapsular ring. If there is perioperative evidence of weak zonular fibers and poor capsular bag stability, one or even two endocapsular rings should be implanted.

**WILLIAM B. TRATTLER, MD**

In patients with pseudoexfoliation, I do not believe that a presbyopia-correcting IOL is the best option because of the potential for late-onset zonular laxity. Over time in pseudoexfoliation patients, the IOL can become decentered. With a monofocal implant, this is often not a major issue, but with a presbyopia-correcting IOL decentration can lead to a significant loss of vision both at distance and near. One option would be to secure the presbyopia-correcting IOL with a suture or explain to the patient in detail that he may require surgery later in life if the IOL decenters.

**ABHAY R. VASAVADA, MS, FRCS**

Pseudoexfoliation is a disorder characterized by deposition of granular-fibrillar material in different parts of the eye. The challenges to the surgeon may include small pupil, poor corneal endothelium, coexisting glaucoma, and zonular weakness. Therefore, I would perform a thorough preoperative evaluation.

The surgical strategy should involve adhering to the princi-

ples of a closed-chamber technique: (1) avoid repeated inflation and deflation of the anterior chamber; (2) use self-sealing small incisions, and (3) inject the ophthalmic viscosurgical device before retracting any instrument from the eye. It is also important to use low fluidics parameters to avoid turbulence in the anterior chamber and allow safe emulsification through small pupils, and perform phaco at the posterior plane, away from the corneal endothelium. Following cortex aspiration, the integrity of the zonules should be assessed. I do not routinely use CTRs if there is no sign of zonular weakness. Moreover, the simple CTR would not address the issue of progressive zonular weakness, even if it is present. If there are signs of zonular weakness, I would implant Ahmed Capsular Tension Segments (Morchers GmbH). Thereafter, I would implant an AcrySof IOL in the bag.

**ROBERT J. WEINSTOCK, MD**

In the presence of pseudoexfoliation, the most important thing for me is a good capsulorrhexis, gentle nuclear rotation, and atraumatic cataract and cortex removal. If this is done and the capsule has good integrity, I am comfortable implanting any IOL, including the Crystalens or a multifocal lens. If there is some zonulolysis, I may insert a CTR and avoid using the Crystalens. ■

*Jorge L. Alió, MD, PhD, is a Professor and the Chairman of Ophthalmology at the Miguel Hernandez University, Alicante, Spain, and the Medical Director of Visum Corp., Spain.*



*Professor Alió states that is a consultant to and/or a clinical investigator for Schwind eye-tech-solutions, Bausch & Lomb, and Carl Zeiss Meditec. He may be reached at tel: +34 96 515 00 25; e-mail: jlalio@visum.com.*

*Roberto Bellucci, MD, is Director of the Ophthalmic Unit Hospital at the University of Verona, Italy. He states that he has no financial interest in the products or companies mentioned. Dr. Bellucci may be reached at tel: +39 045 812 3035; e-mail: roberto.bellucci@azosp.vr.it or robbell@tin.it.*



*Francesco Carones, MD, is the Cofounder and Medical Director of the Carones Ophthalmology Center, Milan, Italy. Dr. Carones states that he is a paid consultant to Alcon Laboratories, Inc. He is a member of the CRST Europe Editorial Board. Dr. Carones may be reached at tel: +39 02 76318174; e-mail: fcarones@carones.com.*



*Charles Cloué, MA(Cantab), MD, DO, FRCS, FRCOphth, FEBO, MAE, is a Consultant Ophthalmic Surgeon at The Queen's University Hospital, BHR Hospitals NHS Trust, London, an Honorary Clinical Lecturer at the University of*





London, and Honorary Consultant Ophthalmologist at the Academic University of Pretoria. Dr. Claoué states that he is a paid consultant to Rayner Intraocular Lenses, Ltd. and also has a patent ownership or part ownership and a royalty agreement with the company. He may be reached at tel: +44 20 88 52 85 22; fax: +44 20 75 15 78 61; e-mail: eyes@dbcg.co.uk.

Jose L. Güell, MD, is the Director of the Cornea and Refractive Surgery Unit at the Instituto de Microcirugía Ocular, Barcelona, Spain, and an Associate Professor of Ophthalmology at the Universitat Autònoma de Barcelona. Dr. Güell states that he is a consultant to Carl Zeiss Meditec AG, Calhoun Vision, Visiometrics SL, and Ophtec. He may be reached at tel: +34 93 253 15 00; e-mail: guell@imo.es.



Oliver K. Klaproth, Dipl Ing(FH), practices at the Johann Wolfgang Goethe-University, Frankfurt, Germany. Dr. Klaproth did not provide financial disclosure information. He may be reached at e-mail: oliver.klaproth@gmx.de.



Thomas Kohnen, MD, is a Professor of Ophthalmology and the Deputy Chairman at the Johann Wolfgang Goethe-University Clinic, Frankfurt, Germany, and Visiting Professor at the Baylor College of Medicine, Houston. Professor Kohnen is a member of the CRST Europe Editorial Board. He did not provide financial disclosure information. He may be reached at tel: +49 69 6301 3945; e-mail: kohnen@em.uni-frankfurt.de.




Frederico F. Marques, MD, PhD, is a Medical Director of the Marques Eye Institute and Surgeon Assistant at the Institute of Cataract, UNIFESP, Sao Paulo, Brazil. He states that he has no financial interest in the products or companies mentioned. Dr. Marques may be reached at tel: +55 11 5677 3513; e-mail: fredani2010@hotmail.com.



Daniela M.V. Marques, MD, PhD, is a Medical Director of the Marques Eye Institute and Surgeon Assistant at the Institute of Cataract, UNIFESP, Sao Paulo, Brazil. She states that she has no financial interest in the products or companies mentioned. Dr. Marques may be reached at tel: +55 11 5677 3513; e-mail: fredani2010@hotmail.com.



Erik L. Mertens, MD, FEBOphth, the Associate Medical Editor of CRST Europe, is Medical Director of Medipolis, Antwerp, Belgium and Medical Director of FYEO Medical, Eersel, the Netherlands. Dr. Mertens states that he is a consultant to STAAR Surgical, Bausch & Lomb, and Alcon Laboratories, Inc. He may be reached at tel: +32 3 828 29 49; e-mail: e.mertens@medipolis.be.



Tobias H. Neuhann, MD, is the Medical Director of AaM Augenklinik am Marienplatz, Munich, Germany. Dr. Neuhann

states that he has no financial interest in the products or companies mentioned. He may be reached at tel: +49 89 230 8890; fax +49 89 230 88910; e-mail: sekretariat@a-a-m.de.

Mark Packer, MD, FACS, is a Clinical Associate Professor at the Casey Eye Institute, Department of Ophthalmology, Oregon Health & Science University, and is in private practice at Drs. Fine, Hoffman & Packer, LLC, Eugene, Oregon. Among his financial interests, Dr. Packer states that he is a consultant to Abbott Medical Optics Inc., Bausch & Lomb, Advanced Vision Science, Carl Zeiss Meditec AG, Carl Zeiss, Inc., Celgene Corp., Ista Pharmaceuticals, Gerson Lehman Group, iTherapeutix, Vistakon, Leerink Swann & Company, Rayner Intraocular Lenses, Ltd., Transcend Medical, Visiogen, Vision Care, WaveTec Vision Systems, and TrueVision Systems. Dr. Packer may be reached at tel: +1 541 687 2110; e-mail: mpacker@finemd.com.



Magda Rau, MD, is the Head of the Augenklinik Cham and Refractive Privatklinik-Dr.Rau in Cham, Germany. Dr. Rau states that she has no financial interest in the products or companies mentioned. She may be reached at tel: +49 9971 861076; e-mail: info@augenklinik-cham.de.



Marie-José Tassignon, MD, PhD, FEBO, is Head of the Department of Ophthalmology at the Antwerp University Hospital, Belgium. Dr. Tassignon states that she has a patent ownership with Morcher GmbH. She may be reached at tel: +32 3 821 33 77; fax +32 3 825 19 26; e-mail: Marie-Jose.Tassignon@uza.be.



William B. Trattler, MD, is a corneal specialist at the Center for Excellence in Eye Care, Miami, and a volunteer Assistant Professor of Ophthalmology at the Bascom Palmer Eye Institute. Dr. Trattler states that he is a consultant, has received research funding, and/or speaking honoraria from Abbott Medical Optics Inc., Lenstec, and/or WaveTec Vision. Dr. Trattler may be reached at tel: +1 305 598 2020; e-mail: wtrattler@earthlink.net.



Abhay R. Vasavada, MS, FRCS, practices at the Iladevi Cataract & IOL Research Centre, Ahmedabad, India. Dr. Vasavada states that he receives travel expenses from Alcon Laboratories, Inc. He may be reached at tel: +91 79 27492303 or +91 79 27490909; fax: +91 79 27411200; e-mail: icirc@abhayvasavada.com.



Robert J. Weinstock, MD, is a cataract and refractive Surgeon at The Eye Institute of West Florida, Largo, Florida. Dr. Weinstock states that he is a consultant to Bausch & Lomb and WaveTec Vision. He may be reached at e-mail: rjweinstock@yahoo.com.

